


PATIENT

Sativa Grimstead

PRESENTING CLINICAL SIGNS

History: Full brother has grade 2-3 murmur.

SPECIES

Canine

ECHOCARDIOGRAM FINDINGS

2D, m-mode, color flow and doppler imaging is available. Normal mitral valve leaflets with no prolapse into the left atrial lumen. No obvious mitral regurgitation with a normal left atrial dimension. Normal LV diameter with adequate myocardial function. The tricuspid valve appears mildly thickened with mild tricuspid regurgitation. Borderline TR velocity. Normal right atrial and ventricular diameter and morphology indicating no overt evidence of pulmonary arterial hypertension. The pulmonic and aortic valves are normal in morphology and mobility. Normal pulmonic and mildly elevated aortic outflow velocities with laminar flow. No obvious aortic and trace pulmonic insufficiency. No pericardial or pleural effusion noted. No obvious cardiac masses.

BREED

American Bulldog

SEX

Female Intact

CARDIAC CHART
AGE

13 months

CANINE CARDIAC PARAMETERS	MR VMAX (m/s)	TR VMAX (m/s)	LA/AO (Boon method)	LA/AO (Heart Base; Swe)	FS (%)	EF (%)	EPSS (cm)
NORMAL PARAMETER	4.5-5.5	<2.7	1.3	<1.6	28-40	40-100	<0.6
PATIENT	NA	2.9	1.3	1.3	43	82	0.35
CANINE CARDIAC PARAMETERS	HR (BPM)	AV VMAX (m/s)	PV MAX (m/s)	BODY WEIGHT (kg)	LA 2D short axis Base view (cm)	LVIDd Avg; 2D and m-mode short axis (cm)	LVIDs Avg; 2D and m-mode short axis (cm)
NORMAL PARAMETER	50-100	0.7-1.7	0.7-1.6	BELOW	BELOW	BELOW	BELOW
PATIENT	110	2.7	1.9	22.7	2.1	4.2	2.4
*Normal chamber parameters expressed as a mean value (SD)				3	1.27 (5.3)	2.46 (2.46)	1.36 (5.5)
BODY WEIGHT DEPENDENT PARAMETERS				5	1.40 (4.5)	2.74 (5.2)	1.60 (4.7)
<i>*Note: All measurements based upon multi-modal images and methods. An average value is reported.</i>				10	1.50 (3.8)	3.27 (3.5)	2.06 (3.1)
				15	1.83 (2.0)	3.71 (2.4)	2.43 (2.1)
				20	2.02 (1.9)	4.14 (2.2)	2.80 (2.0)
				25	2.18 (2.4)	4.48 (2.9)	3.10 (2.5)
				30	2.33 (3.3)	4.83 (3.9)	3.39 (3.4)
				35	2.48 (4.3)	5.17 (5.0)	3.69 (4.5)
				40	2.62 (5.2)	5.48 (6.1)	3.96 (5.4)
				50	2.88 (7.1)	6.07 (8.3)	4.46 (7.4)

WEIGHT

50lbs

INTERPRETED BY

 Maggie Machen Lamy,
 DVM DACVIM
 (Cardiology)

IMAGING PERFORMED BY

Kelly Reschny, RVT

HOSPITAL NAME

 Graham Animal
 Hospital

REFERRING VET

Dr. Collins

INVOICE

21103

DATE

9/20/21

INTERPRETATION OF THE FINDINGS & FURTHER RECOMMENDATIONS

Mild abnormalities are identified. Mild tricuspid regurgitation likely reflects mild tricuspid valve dysplasia given the appearance of the valve. Additionally, a mildly elevated aortic outflow velocity is noted; however, the LVOT/aortic valve are not well visualized. The degree of velocity elevation is mild and is likely of little clinical significance. No obvious pulmonic stenosis is identified, although the outflow velocity is borderline elevated. No additional issues are noted.



PATIENT

Sativa Grimstead

Given a genetic link to pulmonic stenosis and the finding of a mildly abnormal tricuspid valve, breeding is not advised in this animal. That being said, what is seen here is overall mild and likely of little clinical significance to this particular animal.

SPECIES

Canine

Monitor for development of a heart murmur, cough, labored breathing, exercise intolerance or collapse episodes.

BREED

American Bulldog

A recheck echocardiogram is recommended should a significant murmur develop, or signs of cardiac compromise be noted in the future.

IMAGES

SEX

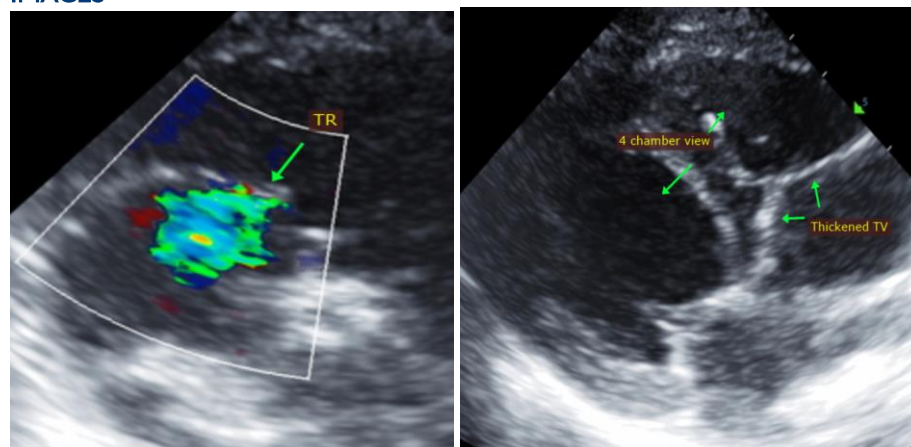
Female Intact

AGE

13 months

WEIGHT

50lbs



INTERPRETED BY

Maggie Machen Lamy,
DVM DACVIM
(Cardiology)

The information and recommendations provided are based on the images presented by the referring veterinarian. No evaluation can be communicated regarding pathology that was not visible in the image/video clips provided.

IMAGING PERFORMED BY

Kelly Reschny, RVT

Thank you for this referral. This report was generated using transcription software, and minor dictation errors may be present. If the clinical or image interpretation does not parallel your findings or if I can be of any further assistance, please contact me.

HOSPITAL NAME

Graham Animal
Hospital

Maggie Machen Lamy, DVM
Diplomate of the American College of Veterinary Internal Medicine (Cardiology)
info@sonopath.com

REFERRING VET

Dr. Collins

INVOICE

21103

DATE

9/20/21